



Clinical Case Study

Speedboat Submucosal Dissection (SSD)

Speedboat UltraSlim submucosal dissection in a polypoid recurrence with severe fibrosis

Dr. Eduardo Albéniz Arbizu

Endoscopy Unit Consultant at Hospital Universitario de Navarra, Spain

Patient History

A 75 year old male with a prior right colectomy for colon cancer. History of fragmented (piecemeal) endoscopic mucosal resection of a flat polyp in the descending colon one year ago.

During the follow-up endoscopy, a recurrence of the lesion with a depressed centre due to scarring and with a tattoo extending to the distal part of the lesion was observed. Endoscopic evaluation showed a JNET IIb pattern, and the lesion size was approximately 25mm.

Complete wall resection was considered but discarded due to the severe fibrosis of the area, after a trial with a plastic cap and foreign body forceps.

Finally, it was decided to perform an endoscopic submucosal dissection, opting for the Speedboat UltraSlim device to facilitate handling of the fibrosis.



Procedure



The lesion was marked using the microwave coagulation function [Fig.1]. Subsequently, a circumferential incision and trimming of the distal portion of the recurrent polyp (anal side) were performed. Expecting to encounter fibrosis, traction was applied using elastic bands and clips (2 clips on the specimen to elevate a larger surface

area and one clip on the contralateral wall slightly distal). Submucosal dissection was then performed with Advanced Bipolar RF Cutting [Fig.2] and Super High Frequency Microwave coagulation until encountering severe central fibrosis with loss of planes [Fig.3].

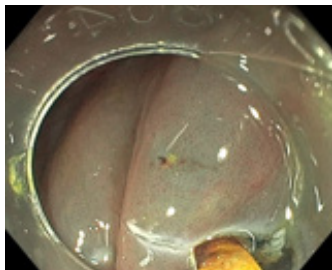


Figure 1: Mucosa

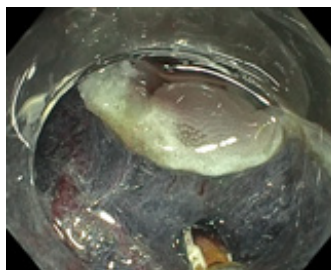

Figure 2: Submucosa

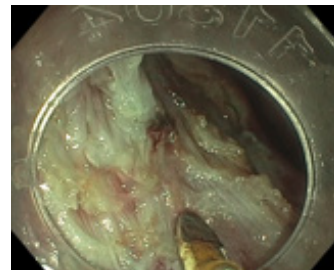


Figure 3: Fibrotic tissue

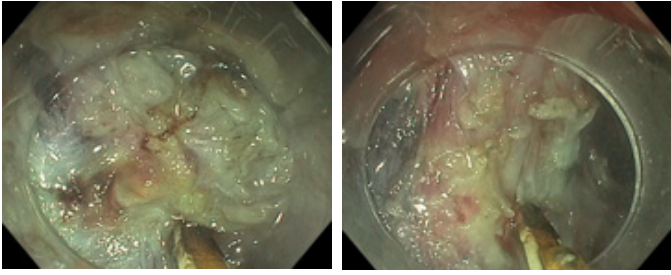


Figure 4: Advanced Bipolar RF cutting and protective hull minimises thermal damage and protects against perforation during dissection

The isolated hull of the Speedboat UltraSlim allowed us to navigate over the fibrosis. The mucosa was damaged very selectively, but the characteristics of the device allowed us to easily recover the plane. After careful dissection of the fibrosis, the ESD was completed conventionally. Advanced Bipolar RF cutting and the protective hull minimises thermal damage and protects against perforation during dissection; especially in complex areas like those encountered in this case with severe fibrosis due to previous treatments and tattooing [Fig. 4].

Outcome

The histology of the lesion revealed an adenoma with high-grade dysplasia extending to the lamina propria [Fig. 5].

The patient was discharged within 24 hours without any complications.

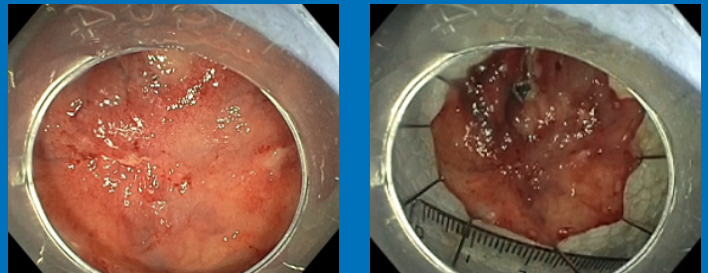


Figure 5: Resected Lesion

Conclusion

The reduced energy required during Advanced Bipolar RF and Super High Frequency Microwave decreases thermal damage. The hull allows navigation over the muscle and careful dissection of complex areas such as severe fibrosis. Speedboat UltraSlim can be used with tunneling dissection techniques but also with any type of traction [Fig.6].

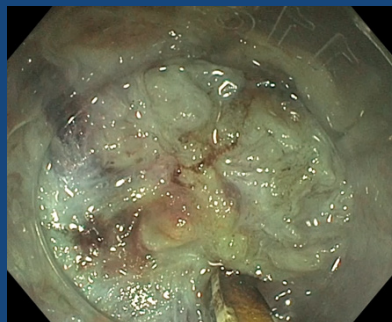


Figure 6: Speedboat UltraSlim facilitates careful dissection of complex areas of severe fibrosis, while utilising lower and controlled energy to decrease thermal damage.